

Peter M. Prendergast

2.1 Introduction

Safe and effective cosmetic surgical practice relies on a clear knowledge and understanding of facial anatomy. Techniques evolve and improve as the complex, layered architecture and soft tissue compartments of the face are discovered and delineated through imaging, staining techniques, and dissections both intraoperatively and in the research laboratory on cadavers [1]. To create a more youthful, natural-looking form, the surgeon endeavors to reverse some of the changes that occur due to aging. These include volumetric changes in soft tissue compartments, gravitational changes, and the attenuation of ligaments. Whether the plan of rejuvenation includes rhytidectomy, platysmaplasty, autologous fat transfer, implants, or endoscopic techniques, a sound knowledge of facial and neck anatomy will increase the likelihood of success and reduce the incidence of undesirable results or complications.

This chapter describes the anatomy of the face in layers or planes, with some important structures or regions described separately, including the facial nerve, sensory nerves, and facial arteries. The superficial layers and topography of the neck are also described. The facial skeleton forms the hard tissue of the face and provides important structural support and projection for the overlying soft tissues, as well as transmitting nerves through foramina and providing attachments for several mimetic muscles and muscles of mastication.

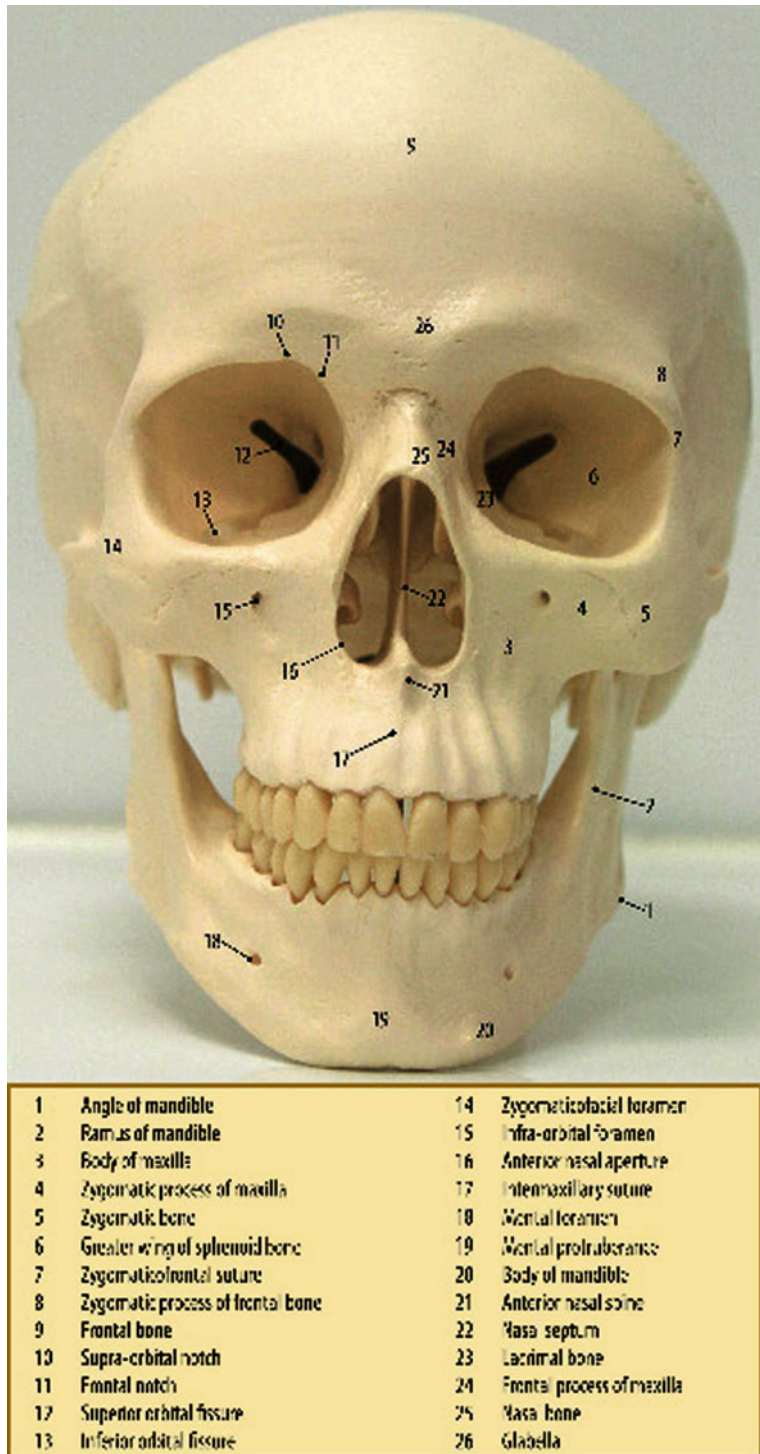
Following a description of the hard tissue foundation, the soft tissues of the face will be described, from superficial to deep, in the following order:

1. Superficial fat compartments
2. Superficial musculoaponeurotic system (SMAS)
3. Retaining ligaments
4. Mimetic muscles
5. Deep plane, including the deep fat compartments

2.2 Facial Skeleton

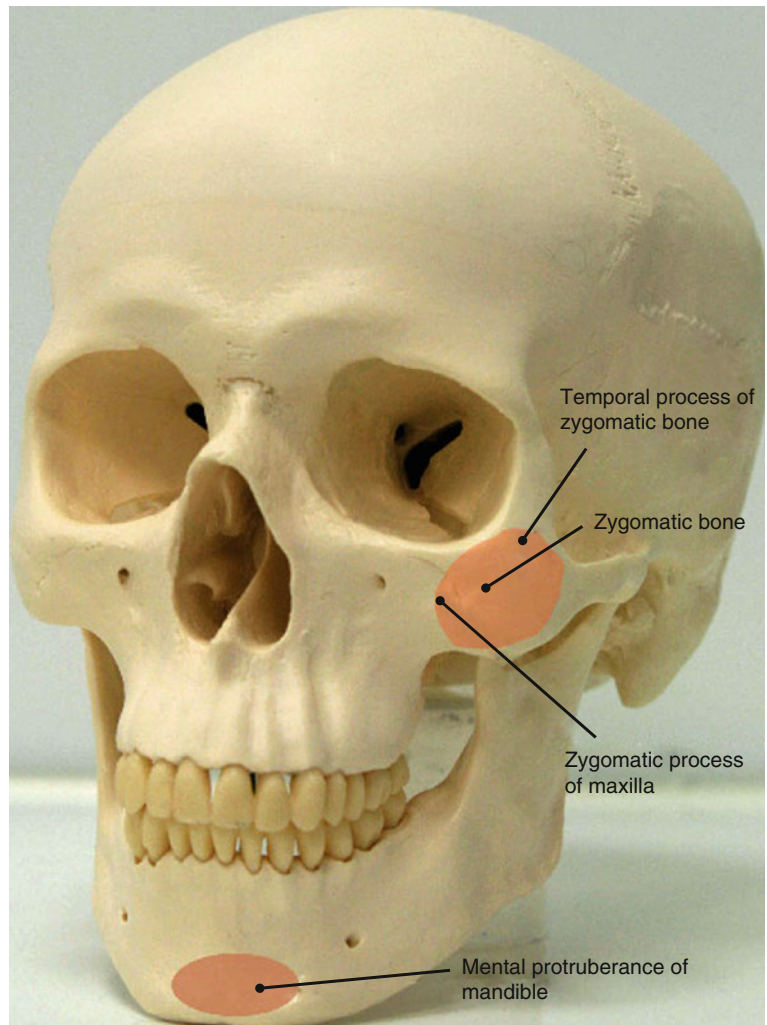
Facial appearance is to a large extent determined by the convexities and concavities of the underlying facial bones (Fig. 2.1). The “high” cheekbones and strong chin associated with attractiveness are attributable to the convexities and projection provided by the zygomatic bone and mental protuberance of the mandible, respectively (Fig. 2.2). The facial skeleton consists of the frontal bone superiorly, the bones of the midface, and the mandible inferiorly. The midface is bounded superiorly by the zygomaticofrontal suture lines, inferiorly by the maxillary teeth, and posteriorly by the sphenothmoid junction and the pterygoid plates. The bones of the midface include the maxillae, the zygomatic bones, palatine bones, nasal bones, zygomatic processes of the temporal bones, lacrimal bones, ethmoid bones, and turbinates. The facial skeleton contains four apertures: the two orbital apertures, the nasal aperture, and the oral aperture. The supraorbital foramen (or notch) and the frontal notch are found at the superior border of each orbit and transmit the supraorbital and supratrochlear nerves, respectively. The maxillary bones contribute to the nasal aperture, bridge of the nose, maxillary teeth, floor of the orbits,

P.M. Prendergast
Venus Medical, Dublin, Ireland
e-mail: peter@venusmed.com

Fig. 2.1 Frontal view of the facial skeleton

and cheekbones. The infraorbital foramen lies in the maxilla below the inferior orbital rim and transmits the infraorbital nerve. The zygomaticofacial foramen transmits the zygomaticofacial nerve inferolateral to the junction of the inferior and lateral orbital rim.

The mandible forms the lower part of the face. In the midline, the mental protuberance gives anterior projection to the overlying soft tissues. Laterally, the ramus of the mandible underlies the masseter muscle and continues superiorly to articulate with the cranium

Fig. 2.2 Convexities of the facial skeleton

through the coronoid process and condylar process of the mandible. The mental nerve emerges from the mental foramen on the body of the mandible in line vertically with the infraorbital and supraorbital nerves.

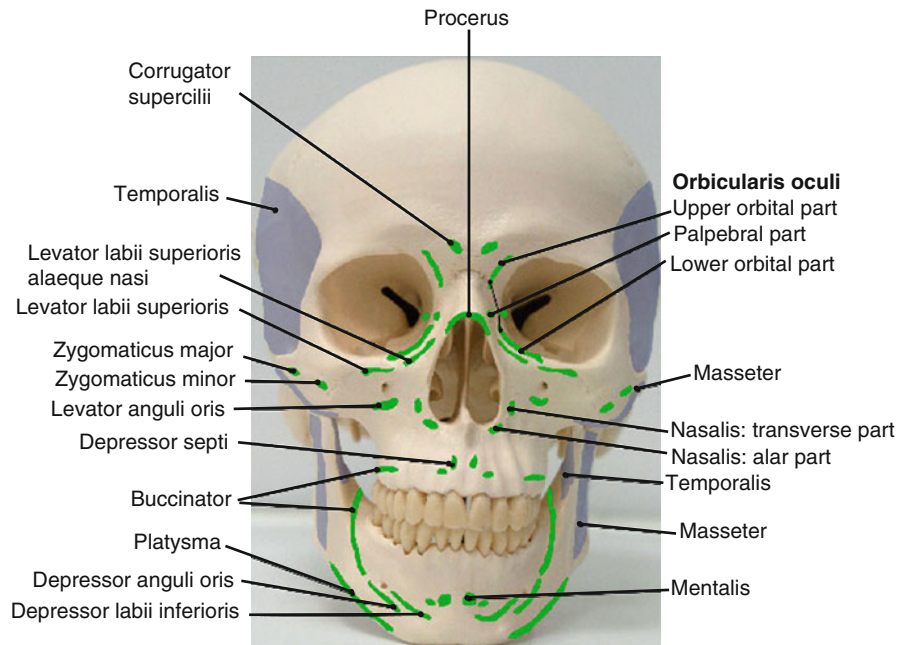
As well as providing structural support, projection, and protection of sensory organs such as the eyes, the facial skeleton provides areas of attachment for the muscles of facial expression and the muscles of mastication (Fig. 2.3).

2.3 Superficial Fat Compartments

The pioneering work of Rohrich and Pessa [2], using staining techniques and cadaver dissections, has revealed a number of distinct superficial fat compartments in the face. These compartments are separated

from one another by delicate fascial tissue and septae that converge where adjacent compartments meet to form retaining ligaments. The superficial fat compartments of the face comprise the following: the nasolabial fat compartment; the medial, middle, and lateral temporal-cheek “malar” fat pads; the central, middle, and lateral temporal-cheek pads in the forehead; and the superior, inferior, and lateral orbital fat pads (Fig. 2.4). Nasolabial fat lies medial to the cheek fat pad compartments and contributes to the overhang of the nasolabial fold. The orbicularis retaining ligament below the inferior orbital rim represents the superior border of the nasolabial fat compartment and the medial cheek compartment (Fig. 2.5). The middle cheek fat compartment lies between the medial and lateral temporal-cheek fat compartments and is bounded superiorly by a band of fascia termed the superior cheek septum. The borders of the middle

Fig. 2.3 Areas of muscle attachments to the facial skeleton



cheek compartment, the inferior, and the lateral orbital fat pad compartments converge to form a tougher band of tissue called the zygomatic ligament [3]. The condensation of connective tissue at the borders of the medial and middle fat compartments correlates with the masseteric ligaments in the same location [4]. The lateral temporal-cheek fat pads span the entire face from the forehead to the cervical area. Its anterior boundary, the lateral cheek septum, is encountered during facelift procedures with medial dissection from the preauricular incision. In the forehead, its upper and lower boundaries are identifiable as the superior and inferior temporal septa. Medial to the lateral temporal-cheek fat compartment in the forehead, the middle temporal fat pad is bounded inferiorly by the orbicularis retaining ligament and medially by the central forehead fat compartment. Above and below the eyes, the superior and inferior orbital fat compartments lie within the perimeter of the orbicularis retaining ligament. These periorbital fat pads are separated from one another medially and laterally by the medial and lateral canthi, respectively. The lateral orbital fat compartment is the third orbital fat pad and is bounded superiorly by the inferior temporal septum and inferiorly by the superior cheek septum. The zygomaticus major muscle attaches, through fibrous septae, to overlying superficial fat compartments along its length. In the lower third of the face, the jowl fat compartment

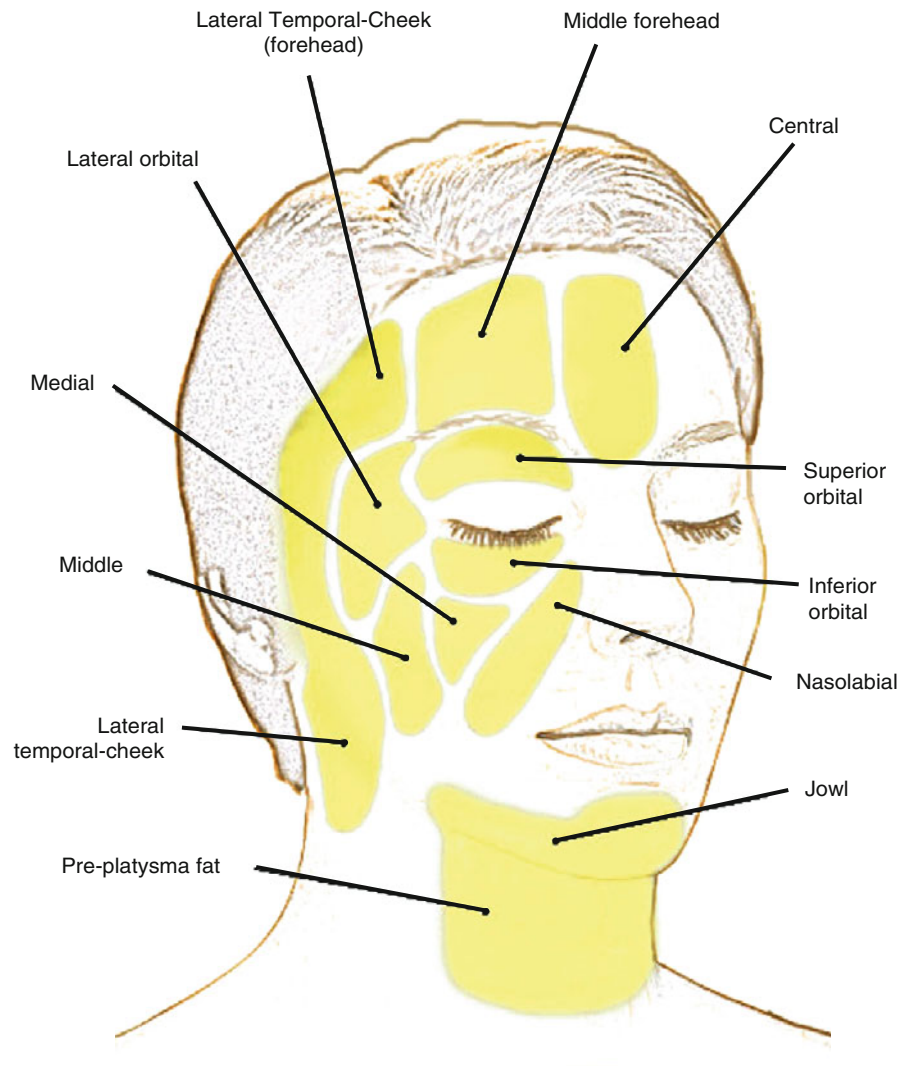
adheres to the depressor anguli oris muscle and is bounded medially by the depressor labii and inferiorly by bands of the platysma muscle. Premental and preplatysmal fat abut the jowl fat compartment.

The compartmentalized anatomy of the superficial subcutaneous fat of the face has implications in the aging process. Volume loss appears to occur at different rates in different compartments, leading to irregularities in facial contour and loss of the seamless, smooth transitions between the convexities and concavities of the face associated with youthfulness and beauty.

2.4 Superficial Musculoaponeurotic System

In 1976, Mitz and Peyronie [5] published their description of a fibrofatty superficial facial fascia they called the superficial musculoaponeurotic system (SMAS). This system or network of collagen fibers, elastic fibers, and fat cells connects the mimetic muscles to the overlying dermis and plays an important functional role in facial expression. The SMAS is central to most current facelift techniques where it is usually dissected, mobilized, and redraped. In simple terms, the SMAS can be considered as a sheet of tissue that extends from the neck (platysma) into the face (SMAS

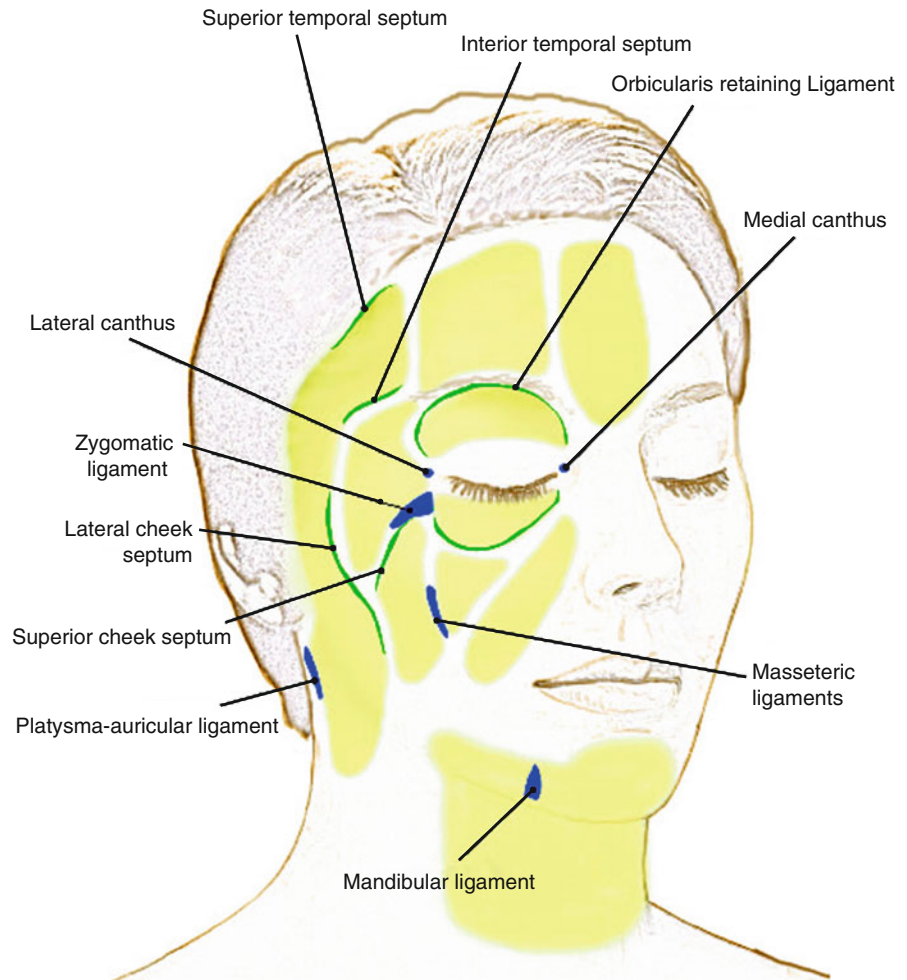
Fig. 2.4 The superficial fat compartments of the face



proper), temporal area (superficial temporal fascia), and medially beyond the temporal crest into the forehead (galea aponeurotica). However, the precise anatomy of the SMAS, regional variations, and even the existence of the SMAS are debated [6]. Ghassemi et al. [7] describe two variations of SMAS architecture. Type I SMAS consists of a network of small fibrous septae that traverse perpendicularly between fat lobules to the dermis and deeply to the facial muscles or periosteum. This variation exists in the forehead, parotid, zygomatic, and infraorbital areas. Type II SMAS consists of a dense mesh of collagen, elastic, and muscle fibers and is found medial to the nasolabial fold, in the upper and lower lips. Although extremely thin, type II SMAS binds the facial muscles around the

mouth to the overlying skin and has an important role in transmitting complex movements during animation. Over the parotid gland, the SMAS is relatively thick. Further medially, it thins considerably making it difficult to dissect. In the lower face, the SMAS covers the facial nerve branches as well as the sensory nerves. Dissection superficial to the SMAS in this region protects facial nerve branches [8]. Above the zygomatic arch, the SMAS exists as the superficial temporal fascia, which splits to enclose the temporal branch of the facial nerve and the intermediate temporal fat pad. Dissection in this area should proceed deep to the superficial temporal fascia, on the deep temporal fascia, to avoid nerve injury. Although considered as one “system” or plane, the surgeon should be mindful of

Fig. 2.5 Ligaments and septa between fat compartments of the face



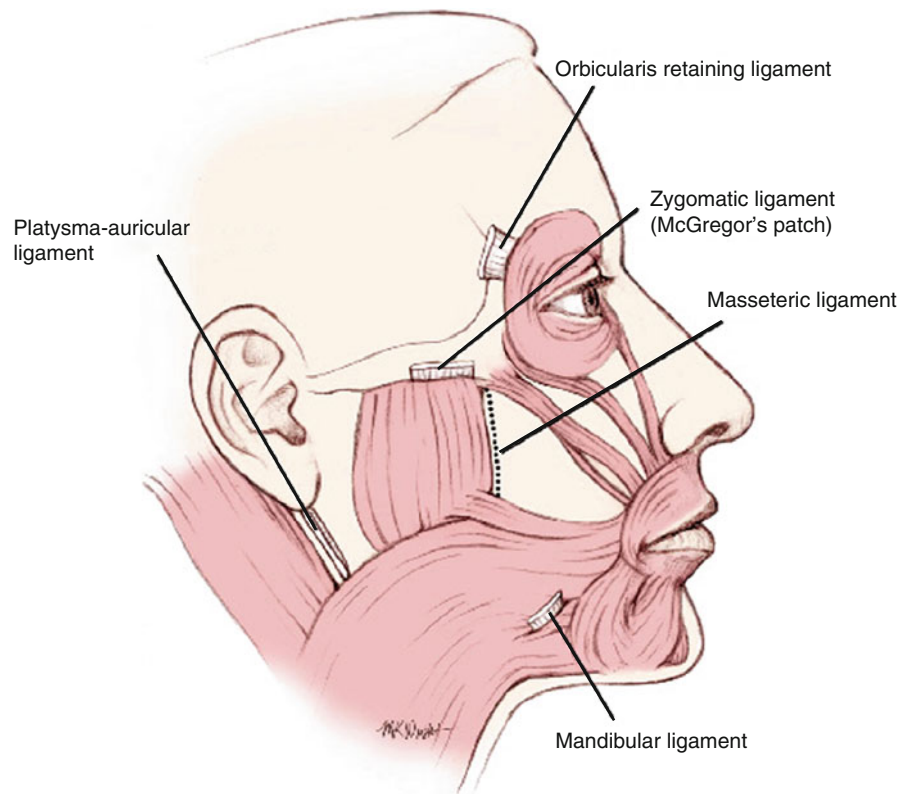
the regional differences in SMAS anatomy from superior to inferior and lateral to medial.

2.5 Retaining Ligaments

True retaining ligaments are easily identifiable structures that connect the dermis to the underlying periosteum. False retaining ligaments are more diffuse condensations of fibrous tissue that connect superficial and deep facial fasciae [9] (Fig. 2.6). The zygomatic ligament (McGregor's patch) is a true ligament that connects the inferior border of the zygomatic arch to the dermis and is found just posterior to the origin of the zygomaticus minor muscle [3]. Other true ligaments include the lateral orbital thickening on the superolateral orbital rim that arises as a thickening of the orbicularis retaining ligament, and the mandibular

retaining ligament. The latter connects the periosteum of the mandible just medial to the origin of depressor anguli oris to the overlying dermis. This attachment gives rise to the labiomandibular fold just anterior to the jowl. The masseteric ligaments are false retaining ligaments that arise from the anterior border of the masseter and insert into the SMAS and overlying dermis of the cheek. With aging, these ligaments attenuate, the SMAS over the masseter becomes ptotic, and this leads to the formation of jowls [10]. Below the lobule of the ear, the platysma-auricular ligament represents a condensation of fibrous tissue where the lateral temporal-cheek fat compartment meets the postauricular fat compartment. During facial rejuvenation procedures, true and false retaining ligaments are encountered and often released in order to mobilize and redrape tissue planes. Extra care should be taken when releasing ligaments as important facial nerve

Fig. 2.6 The retaining ligaments of the face



branches are intimately related to ligaments, such as the zygomatic and mandibular retaining ligaments.

2.6 Mimetic Muscles

The muscles of facial expression are thin, flat muscles that act either as sphincters of facial orifices, as dilators, or as elevators and depressors of the eyebrows and mouth. Frontalis, corrugator supercilii, depressor supercilii, procerus, and orbicularis oculi represent the periorbital facial muscles. The perioral muscles include the levator muscles, zygomaticus major and minor, risorius, orbicularis oris, depressor anguli oris, depressor labii, and mentalis. The nasal group includes compressor naris, dilator naris, and depressor septi. In the neck, the platysma muscle lies superficially and extends into the lower face (Fig. 2.7).

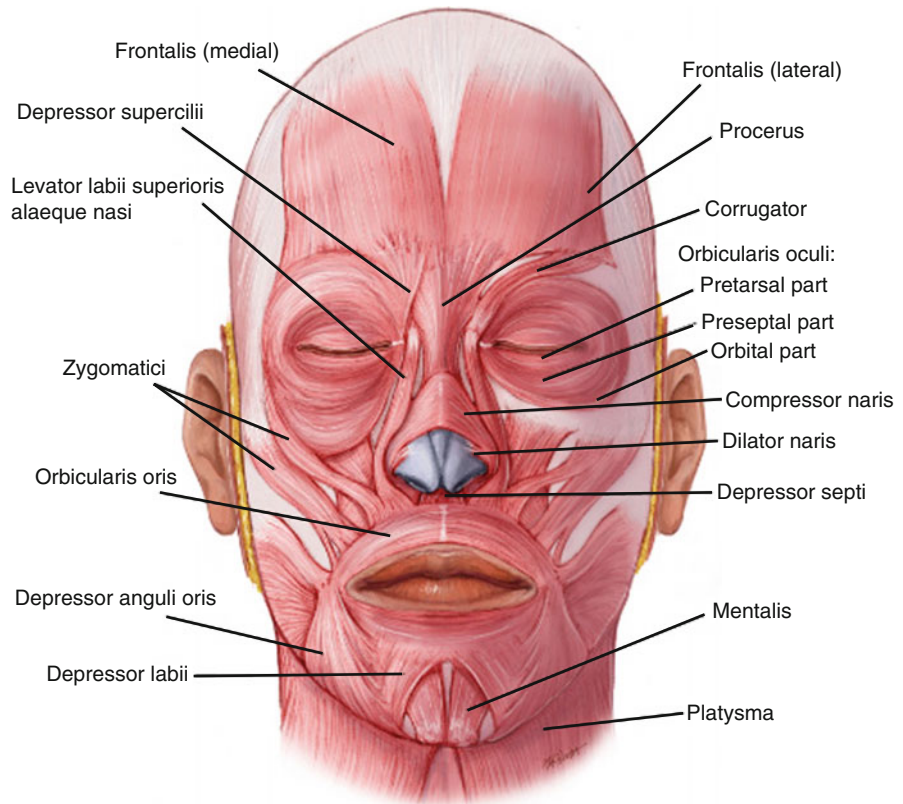
Frontalis represents the anterior belly of the occipitofrontalis muscle and is the main elevator of the brows. It arises from the epicranial aponeurosis and passes forward over the forehead to insert into fibers of the orbicularis oculi, corrugators, and dermis over the brows.

Contraction raises the eyebrows and causes horizontal furrows over the forehead. Frontalis receives innervation from the temporal branch of the facial nerve.

Orbicularis oculi acts as a sphincter around the eye. It consists of three parts, the orbital, preseptal, and pretarsal parts. The orbital part arises from the nasal part of the frontal bone, the frontal process of the maxilla, and the anterior part of the medial canthal tendon. Its fibers pass in concentric loops around the orbit, well beyond the confines of the orbital rim. Contraction causes the eyes to squeeze closed forcefully. Superior fibers also depress the brow. Preseptal orbicularis oculi arises from the medial canthal tendon, passes over the fibrous orbital septum of the orbital rim, and inserts into the lateral palpebral raphe. The pretarsal portion, involved in blinking, overlies the tarsal plate of the eyelid and has similar origins and insertions to its preseptal counterpart. These muscles receive innervation from the temporal and zygomatic branches of the facial nerve.

Corrugator supercilii arises from the superomedial aspect of the orbital rim and passes upward and outward to insert into the dermis of the middle of the brow. From its origin deep to frontalis, two slips of

Fig. 2.7 The mimetic facial muscles



muscle, one vertical and one transverse, pass through fibers of frontalis to reach the dermis. The superficial and deep branches of the supraorbital nerve are intimately related to corrugator supercilii at its origin and are prone to injury during resection of this muscle. Corrugator supercilii depresses the brow and pulls it medially, as in frowning.

Depressor supercilii is a thin slip of muscle that is difficult to distinguish from the superomedial fibers of orbicularis oculi. It inserts into the medial brow and acts as a depressor.

Procerus arises from the nasal bone, passes superiorly, and inserts into the dermis of the glabella between the brows. It depresses the lower forehead skin in the midline to create a horizontal crease at the bridge of the nose. Chemodenervation of procerus and corrugator supercilii to alleviate frown lines is one of the most common aesthetic indications for botulinum toxins. Procerus is sometimes debulked during endoscopic brow lift procedures to reduce the horizontal frown crease.

Zygomaticus major and minor are superficial muscles that originate from the body of the zygoma and pass downwards to insert into the corner of the mouth

and lateral aspect of the upper lip, respectively. They receive their nerve supply on their deep surface from the zygomatic and buccal branches of the facial nerve. Zygomaticus major and minor lift the corners of the mouth.

Levator labii lies deep to orbicularis oculi at its origin from the maxilla just above the infraorbital foramen. It passes downward to insert into the upper lip and orbicularis oris. A smaller slip of muscle medial to this, levator labii superioris alaeque nasi, originates from the frontal process of the maxilla and inserts into the nasal cartilage and upper lip. Both of these muscles are supplied from branches of the zygomatic and buccal branches of the facial nerve and elevate the upper lip.

Levator anguli oris arises deeply from the canine fossa of the maxilla below the infraorbital foramen and inserts into the upper lip. It is innervated on its superficial aspect by the zygomatic and buccal branches of the facial nerve and elevates the corner of the mouth.

Risorius is often underdeveloped and arises from a thickening of the platysma muscle over the lateral cheek, the parotidomasseteric fascia, or both. It inserts into the corner of the mouth and pulls the mouth corners laterally.

Orbicularis oris acts as a sphincter around the mouth and its fibers interlace with all of the other facial muscles that act on the mouth. The buccal and marginal mandibular branches of the facial nerve provide motor supply to orbicularis oris, which has various actions, including pursing, dilation, and closure of the lips.

Depressor anguli oris arises from the periosteum of the mandible along the oblique line lateral to depressor labii inferioris. Its fibers converge on the modiolus with fibers of orbicularis oris, risorius, and sometimes levator anguli oris. It is supplied by the marginal mandibular branch of the facial nerve and depresses the mouth corners on contraction. Depressor labii inferioris arises from the oblique line of the mandible in front of the mental foramen, where fibers of depressor anguli oris cover it. It passes upward and medially to insert into the skin and mucosa of the lower lip and into fibers of orbicularis oris.

Mentalis arises from the incisive fossa of the mandible and descends to insert into the dermis of the chin. Contraction elevates and protrudes the lower lip and creates the characteristic “peach-pit” dimpling of the skin over the chin. Motor supply arises from the marginal mandibular nerve.

Nasalis consists of two parts, the transverse part (compressor naris) and alar part (dilator naris). Compressor naris arises from the maxilla over the canine tooth and passes over the dorsum of the nose to interlace with fibers from the contralateral side. It compresses the nasal aperture. Dilator naris originates from the maxilla just below and medial to compressor naris and inserts into the alar cartilage of the nose. It dilates the nostrils during respiration. Depressor septi is a slip of muscle arising from the maxilla above the central incisor, deep to the mucous membrane of the upper lip. It inserts into the cartilaginous nasal septum and pulls the nose tip inferiorly. Nasalis and depressor septi receive innervation from the superior buccal branches of the facial nerve.

2.7 Deep Plane Including the Deep Fat Compartments

The superficial fat compartments described above lie above the muscles of facial expression in the subcutaneous plane. In the midface, the suborbicularis oculi fat and deep cheek fat represent deeper fat compartments that provide volume and shape to the face and act as gliding planes within which the muscles of facial

expression can move freely. Suborbicularis oculi fat (SOOF) has two parts, medial and lateral [11]. The medial component extends along the inferior orbital rim from the medial limbus (sclerocorneal junction) to the lateral canthus and the lateral component from the lateral canthus to the temporal fat pad. Between the SOOF and the periosteum of the zygomatic process of maxilla, there is a gliding space, the prezygomatic space [12]. This space is bounded superiorly by the orbicularis retaining ligament and inferiorly by the zygomatic retaining ligament (Fig. 2.8). The sublevator fat pad lies medial to the medial SOOF compartment and represents the most medial of the deep infraorbital fat pads. This fat pad is an extension of the buccal fat pad, behind levator labii superioris alaeque nasi and is continuous below and laterally with the melolabial and buccal extensions of the buccal fat pad [1]. The buccal fat pad is an aesthetically important structure that sits on the posterolateral part of the maxilla superficial to the buccinator muscle and deep to the anterior part of masseter. Functionally, it facilitates a free gliding movement for the surrounding muscles of mastication [13]. As well as the medial extensions described above, it continues laterally as the pterygoid extension (Fig. 2.9). Buccal branches of the facial nerve and the parotid duct travel along its surface within the parotidomasseteric fascia after leaving the parotid gland.

The galea fat pad lies deep to frontalis in the forehead and extends superiorly for about 3 cm [14]. It envelops corrugator and procerus and aids gliding of these muscles during animation. The retro-orbicularis oculi fat (ROOF) is part of the galea fat pad over the superolateral orbital rim from the middle of the rim to beyond the lateral part. It lies deep to the superolateral fibers of preseptal and orbital orbicularis oculi and contributes to the fullness (in youth) and heaviness (in senescence) of the lateral brow and lid.

With aging, the retaining ligaments under the eye attenuate. This, together with volume loss in the superficial and deep fat compartments, results in visible folds and grooves in the cheeks and under the eyes (Fig. 2.10).

The deep cervical fascia covering sternocleidomastoid in the neck continues upward to ensheath the parotid gland between the mandible and mastoid process. The layer of fascia covering the parotid gland and masseter, termed parotidomasseteric fascia, continues superiorly to insert into the inferior border of the zygomatic arch. In the temporal area, the corresponding fascia in the same plane is present as deep temporal

Fig. 2.8 The prezygomatic space. This space extends anteriorly to the infraorbital area

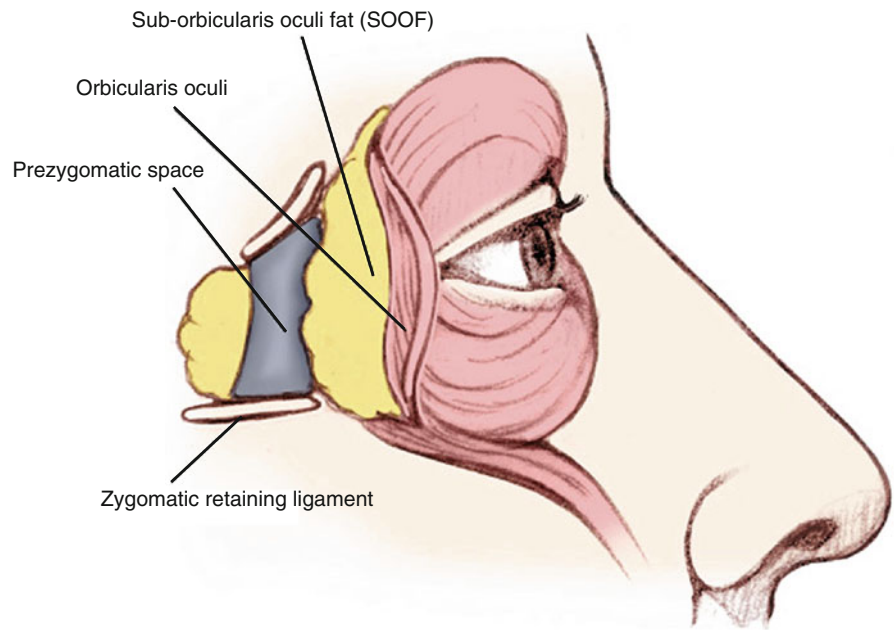
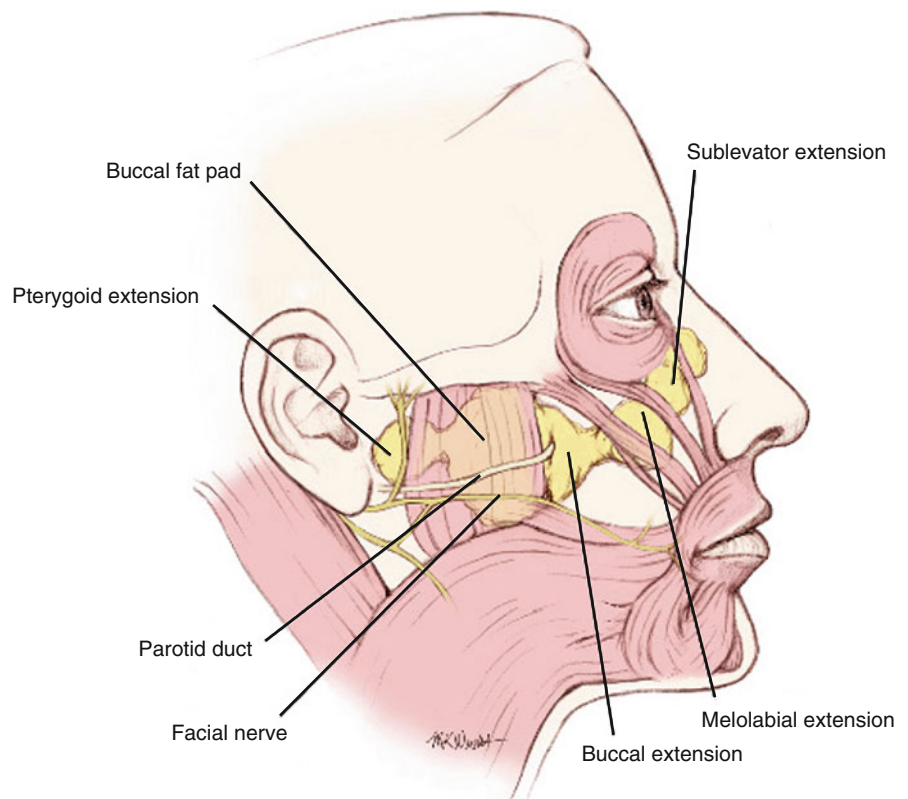


Fig. 2.9 The buccal fat pad and its extensions



fascia, which inserts into the superior border of the zygomatic arch. In the lower face, branches of the facial nerve lie underneath the deep fascia, whereas

above the zygomatic arch and in the upper face, facial nerve branches lie superficial to the deep fascia and are susceptible to injury during superficial dissections.

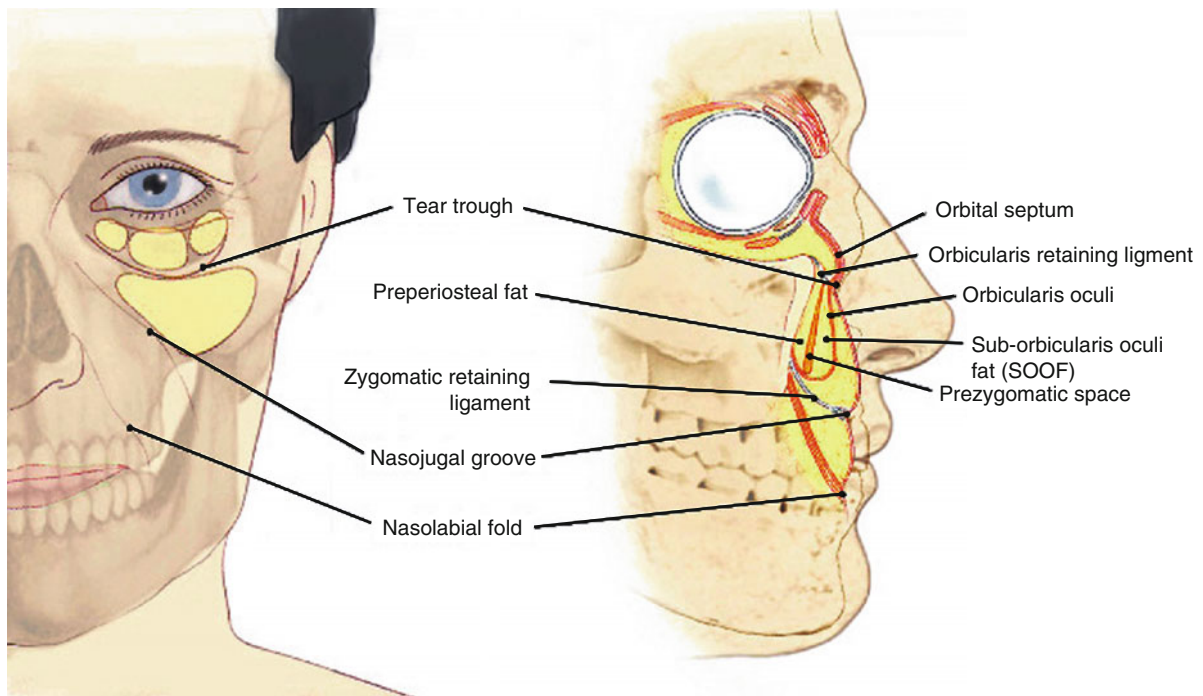


Fig. 2.10 Frontal and lateral view of attenuated ligaments in the midface

2.8 Neck

Surgical rejuvenation of the neck is frequently included in an overall plan of facial rejuvenation to maintain harmony and enhance results. Cosmetic surgical procedures in the neck typically address the superficial structures: skin, subcutaneous fat, and platysma. Occasionally, subplatysmal fat and even the digastric muscles are partially resected to improve neck contour [15, 16]. The aim of surgery is to improve or restore the definition of the topographical landmarks of the neck. These include a sharp mento-cervical angle, defined mandibular border, and prominent anterior border of sternocleidomastoid.

The neck can be divided into anterior, posterior, posterior cervical, and sternocleidomastoid regions (Fig. 2.11). Most cosmetic surgical intervention takes place in the anterior region or triangle. The contents of each region are described in Table 2.1.

Just beneath the skin in the anterior cervical triangle lies the platysma muscle. Platysma is a broad thin sheet of muscle that arises from the fascia of the muscles of the chest and shoulders and passes upward over the clavicles and neck toward the lower face. Along its

course, platysma covers the medial part of sternocleidomastoid, transverse cervical and greater auricular nerves, cervical and mandibular branches of the facial nerve, the facial vessels, the submandibular gland, and inferior part of the parotid [17] (Fig. 2.12). Fibers insert into the border of the mandible, perioral muscles, modiolus, and dermis of the cheek. Although variations exist [18], platysma usually decussates with fibers from the other side 1–2 cm below the mandible. As part of aging, its medial fibers attenuate or thicken to create platysmal bands. Functionally, platysma depresses the mandible during deep inspiration but is probably more important as a mimetic muscle to express horror or disgust. It is regarded as the inferior most extension of the SMAS and is innervated by the cervical branch of the facial nerve.

Between platysma and sternocleidomastoid, there is a loose connective tissue layer termed the superficial cervical fascia. This plane allows platysma to glide easily over sternocleidomastoid and enables effective minimally invasive suture lifting of platysma [19]. The free edge of platysma is usually located about 3 cm below the border of the mandible just anterior to the anterior border of sternocleidomastoid.

Fig. 2.11 The triangles of the neck

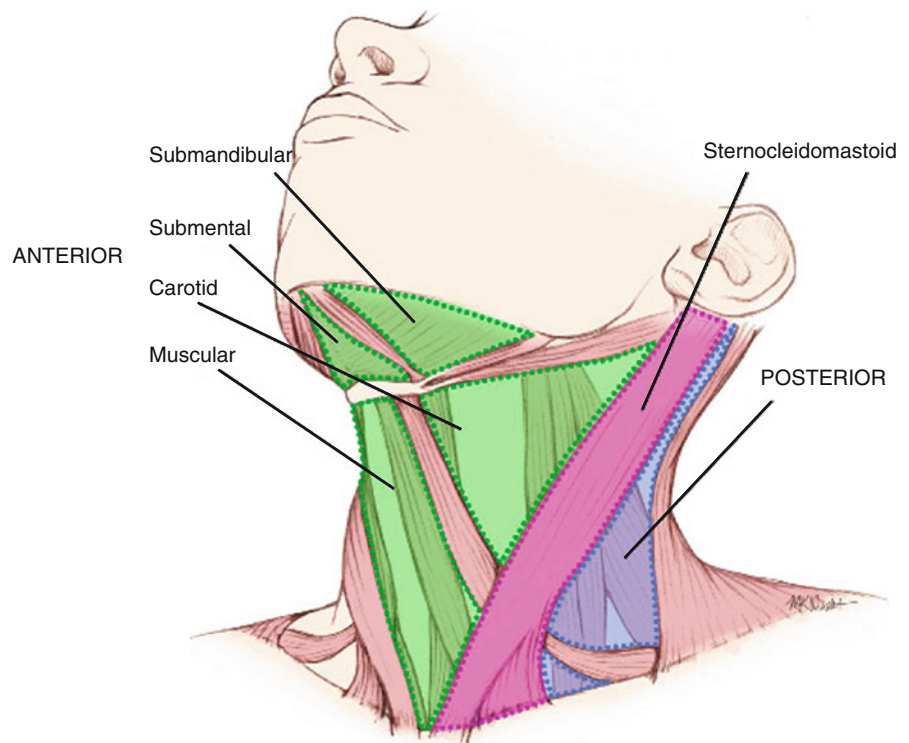


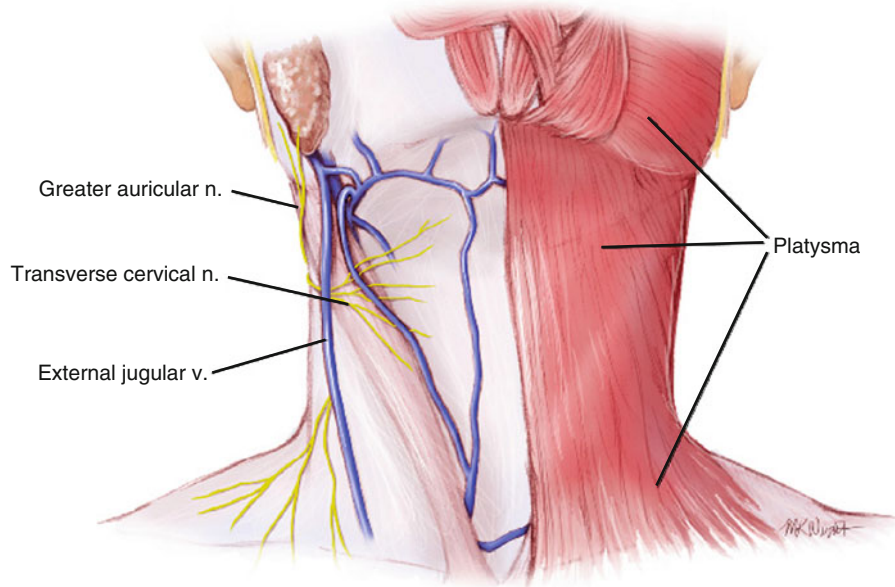
Table 2.1 Regions of the neck

Division	Subdivision	Contents
Anterior triangle	Submandibular triangle	Submandibular gland and nodes; facial and submental vessels; hypoglossal, glossopharyngeal, and mylohyoid nn.
	Submental triangle	Submental nodes and anterior jugular veins
	Muscular triangle	Sternothyroid and sternohyoid muscles, thyroid and parathyroid glands
	Carotid triangle	Bifurcation of carotid, carotid body, hypoglossal, and vagus nn.
Sternocleidomastoid		Sternocleidomastoid, carotid sheath with carotid a., internal jugular v., vagus n., lymph nodes
Posterior triangle	Supraclavicular triangle	Part of brachial plexus, subclavian a., superficial cervical and suprascapular vessels, termination of external jugular v.
	Occipital triangle	Accessory n., trunks of brachial plexus, occipital a., cutaneous branches of cervical plexus
Posterior cervical		Vertebral a., cervical plexus, nuchal muscles

The anterior cervical triangle is bounded posteriorly by the anterior border of sternocleidomastoid, anteriorly by the median line of the neck, and superiorly by the inferior border of the mandible. The triangle is further divided into submandibular, submental, muscular, and carotid triangles by digastric and omohyoid muscles (Fig. 2.11). An intermediate tendon, attached to the greater horn of the hyoid bone, divides the digastric into posterior and anterior bellies. The posterior belly arises from the mastoid notch behind the mastoid process of

the temporal bone. It passes anteriorly and inferiorly below the mandible toward the hyoid bone where it becomes the digastric tendon. The digastric tendon passes through the intermediate tendon and arises anteriorly as the anterior belly of digastric. The anterior belly inserts into the digastric fossa on the inferior border of the mandible near the midline. Digastric muscle serves to depress and retract the mandible and support the hyoid bone. It can be felt as a fleshy mass under the chin when the tongue is retracted.

Fig. 2.12 Neck region showing platysma and underlying structures



2.9 Facial Nerve

The facial nerve (seventh cranial nerve) provides motor innervation to the muscles of facial expression. It begins in the face by emerging from the stylomastoid foramen 6–8 mm medial to the tympanomastoid suture of the skull. Before entering the substance of the parotid gland, the posterior auricular nerve and nerves to the posterior belly of digastric and stylohyoid branch from the main trunk. Within the parotid gland, the facial nerve divides into its main branches: temporal branch, zygomatic branch, buccal branch, marginal mandibular branch, and cervical branch (Fig. 2.13).

The temporal branch of the facial nerve leaves the superior border of the parotid gland as three or four rami. They cross the zygomatic arch between 0.8 and 3.5 cm anterior to the external acoustic meatus, and usually about 2.5 cm anterior to it. At the level of the zygomatic arch, the most anterior branch is always at least 2 cm posterior to the lateral orbital rim. The temporal branches pass in an envelope of superficial temporal fascia with the intermediate fat pad, superficial to the deep temporal fascia. The temporal branch enters frontalis about 2 cm above the brow, just below the anterior branch of the superficial temporal artery.

There are up to three zygomatic branches of the facial nerve. The upper branch passes above the eye to supply frontalis and orbicularis oculi. The lower branch always passes under the origin of zygomaticus major and supplies this muscle, other lip elevators, and the

lower orbicularis oculi. Smaller branches continue around the medial aspect of the eye to supply depressor supercillii and the superomedial orbicularis oculi.

The buccal branch exits the parotid and is tightly bound to the anterior surface of masseter within the parotidomasseteric fascia. It continues anteriorly over the buccal fat pad, below and parallel to the parotid duct, to supply the buccinators and muscles of the upper lip and nose. A second branch is occasionally present, but this travels superior to the parotid duct in its course anteriorly.

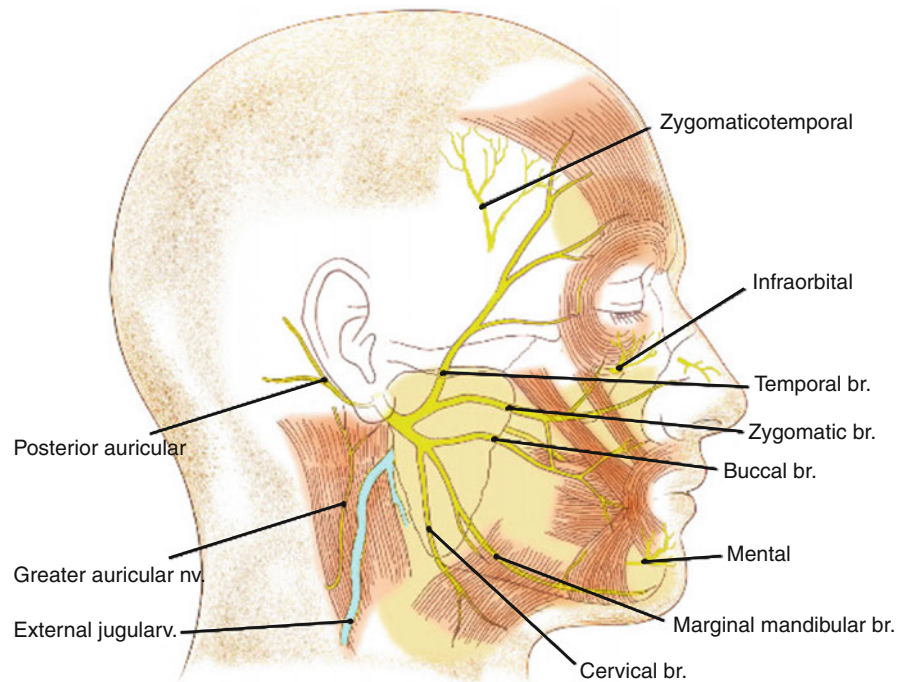
The marginal mandibular nerve exits the lower part of the parotid gland as one to three major branches. It usually runs above the inferior border of the mandible, but may drop up to 4 cm below it. About 2 cm posterior to the angle of the mouth, the nerve passes upward and more superficially to innervate the lip depressors. Although it remains deep to the platysma, it is vulnerable to injury during surgical procedures in the lower face at this location.

The cervical branch of the facial nerve passes into the neck at the level of the hyoid bone to innervate the platysma muscle.

2.10 Sensory Nerves

The sensory innervation of the face is via the three divisions of the trigeminal nerve (fifth cranial nerve): ophthalmic nerve, maxillary nerve, and mandibular

Fig. 2.13 Branches of the facial nerve. *Note:* The greater auricular, zygomaticotemporal, infraorbital, and mental nerves are sensory nerves



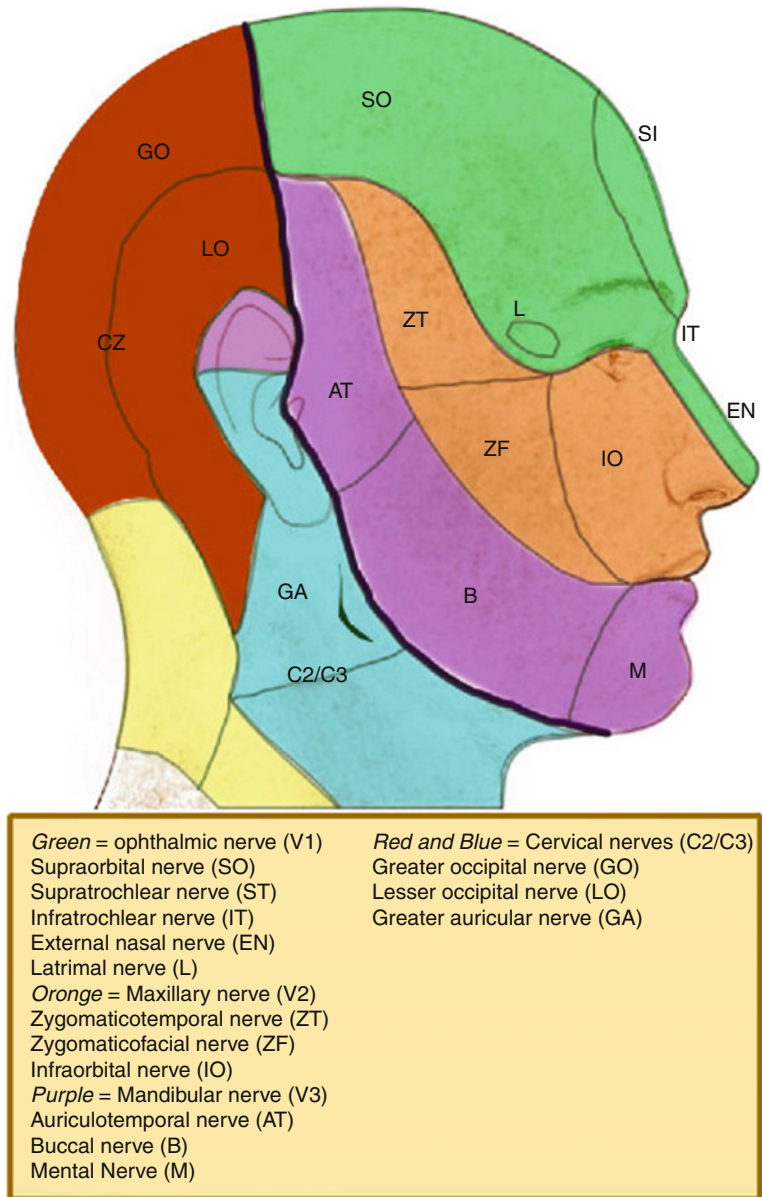
nerve. The ophthalmic nerve supplies the forehead, upper eyelid, and dorsum of the nose via the supraorbital, supratrochlear, infratrochlear, lacrimal, and external nasal nerves. The maxillary nerve supplies the lower eyelid, cheek, upper lip, ala of the nose, and part of the temple through the infraorbital, zygomaticofacial, and zygomaticotemporal nerves. The maxillary nerve also supplies the maxillary teeth and nasal cavity via the alveolar nerves and pterygopalatine nerves, respectively. The mandibular nerve has motor and sensory fibers. Its branches include the inferior alveolar nerve, lingual nerve, buccal nerve, and auriculotemporal nerve. These supply the skin over the mandible, lower cheek, part of the temple and ear, the lower teeth, gingival mucosa, and the lower lip (Fig. 2.14). The greater auricular nerve, derived from the anterior primary rami of the second and third cervical nerves, supplies the skin over the angle of the mandible.

The supraorbital nerve emerges from the orbit at the supraorbital notch (or foramen) 2.3–2.7 cm from the midline in men and 2.2–2.5 cm from the midline in women [20]. It has superficial and deep branches that straddle the corrugator muscle. Sometimes, these branches exit from separate foramina, the deep branch arising lateral to the superficial one. The deep branch usually runs superiorly between the galea and the

periosteum of the forehead 0.5–1.5 cm medial to the superior temporal crest line.

The supratrochlear nerve exits the orbit about 1 cm medial to the supraorbital nerve and runs close to the periosteum under the corrugator and frontalis. Its several branches supply the skin over the medial eyelid and lower medial forehead. The infratrochlear nerve is a terminal branch of the nasociliary nerve that supplies a small area on the medial aspect of the upper eyelid and bridge of the nose. The external nasal nerve supplies the skin of the nose below the nasal bone, except for the skin over the external nares. The lacrimal nerve supplies the skin over the lateral part of the upper eyelid.

The infraorbital nerve is the largest cutaneous branch of the maxillary nerve. It enters the face through the infraorbital foramen 2.7–3 cm from the midline in men and 2.4–2.7 cm from the midline in women, about 7 and 6 mm inferior to the inferior orbital rim in men and women, respectively. The nerve appears from the foramen just below the origin of levator labii superioris. It supplies the lower eyelid, ala of the nose, and upper lip. The zygomaticofacial nerve arises from the zygomaticofacial foramen below and lateral to the orbital rim and supplies skin of the malar eminence. The zygomaticotemporal nerve emerges from its foramen on the deep surface of the zygomatic bone and supplies the anterior temple.

Fig. 2.14 Sensory innervation of the face

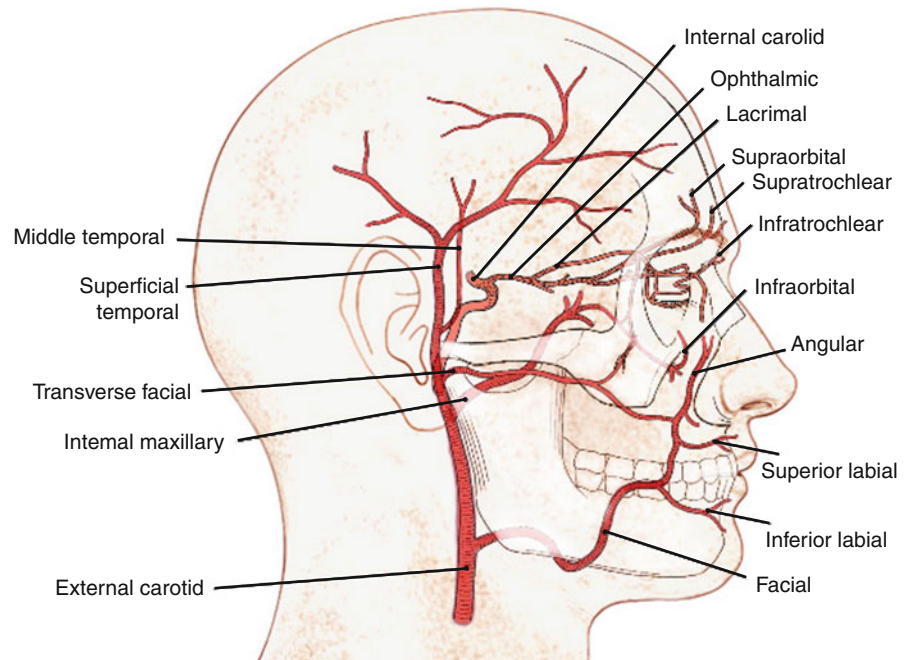
The mental nerve is a branch of the inferior alveolar nerve that exits the mental foramen in line vertically with the infraorbital foramen, between the apices of the pre-molar teeth. It is often visible and easily palpable through stretched oral mucosa. It supplies the skin over the lower lip and mandible. The buccal branch of the mandibular nerve supplies the buccal mucosa and skin of the cheek, and the lingual nerve provides sensory innervation to the anterior two-thirds of the tongue and the floor of the mouth. The auriculotemporal nerve emerges from behind the temporomandibular joint to supply the skin of the

upper one-third of the ear, the external acoustic meatus, tympanic membrane, as well as the skin over the temporal region. Secretomotor fibers also pass via the auriculotemporal nerve to the parotid gland.

2.11 Arteries of the Face

The skin and soft tissue of the face receive their arterial supply from branches of the facial, maxillary, and superficial temporal arteries – all branches of the

Fig. 2.15 Arterial supply to the face



external carotid artery. The exception is a mask-like area, including the central forehead, eyelids, and upper part of the nose, which are supplied through the internal carotid system by the ophthalmic arteries (Fig. 2.15).

The facial artery arises from the external carotid and loops around the inferior and anterior borders of the mandible, just anterior to the masseter. It pierces the masseteric fascia and ascends upward and medially toward the eye. It lies deep to the zygomaticus and risorius muscles but superficial to buccinator and levator anguli oris [21]. At the level of the mouth, the facial artery sends two labial arteries, inferior and superior, into the lips where they pass below orbicularis oris. The continuation of the facial artery near the medial canthus beside the nose is the angular artery.

The maxillary artery is a terminal branch of the external carotid with three main branches, mental, buccal, and infraorbital arteries. The mental artery is the terminal branch of the inferior alveolar artery that passes through the mental foramen to supply the chin and lower lip. The buccal artery crosses the buccinators to supply the cheek tissue. The infraorbital artery reaches the face through the infraorbital foramen and supplies the lower eyelid, cheek, and lateral nose. It anastomoses with branches of the transverse facial, ophthalmic, buccal, and facial arteries.

The superficial temporal artery is the terminal branch of the external carotid artery. In the substance

of the parotid, just before reaching the zygomatic arch, it gives off the transverse facial artery which runs inferior and parallel to the arch and supplies the parotid, parotid duct, masseter, and skin of the lateral canthus. The superficial temporal artery crosses the zygomatic arch superficially within the superficial temporal fascia. Above the arch, it gives off a middle temporal artery that pierces the deep temporal fascia and supplies the temporalis muscle. Thereafter, about 2 cm above the zygomatic arch, the superficial temporal artery divides into anterior and posterior branches. The anterior branch supplies the forehead and forms anastomoses with the supraorbital and supratrochlear vessels. The posterior part supplies the parietal scalp and periosteum.

The ophthalmic artery is a branch of the internal carotid system (Fig. 2.15). Its branches include the lacrimal, supraorbital, supratrochlear, infratrochlear, and external nasal arteries. There is significant communication between the external and internal carotid artery systems around the eye through several anastomoses. Inadvertent intra-arterial injection of fillers for soft tissue augmentation around the eye can lead to occlusion of the central retinal vessels and potentially blindness [22–24]. To avoid this complication, fillers should be injected in small volumes using blunt cannulas and a careful retrograde injection technique [25].

References

1. Gassner HG, Rafii A, Young A, Murakami C, Moe K, Larrabee WF (2008) Surgical anatomy of the face. Implications for modern face-lift techniques. *Arch Facial Plast Surg* 10(1):9–19
2. Rohrich RJ, Pessa JE (2007) The fat compartments of the face: anatomy and clinical implications for cosmetic surgery. *Plast Reconstr Surg* 119(7):2219–2227
3. Furnas DW (1989) The retaining ligaments of the cheek. *Plast Reconstr Surg* 83(1):11–16
4. Stuzin JM, Baker TJ, Gordon HL (1992) The relationship of the superficial and deep facial fascias: relevance to rhytidectomy and aging. *Plast Reconstr Surg* 89(3):441–449
5. Mitz V, Peyronie M (1976) The superficial musculo-aponeurotic system in the parotid and cheek area. *Plast Reconstr Surg* 58(1):80–88
6. Gardetto A, Dabernig J, Rainer C, Piegger J, Piza-Katzer H, Fritsch H (2003) Does a superficial musculoaponeurotic system exist in the face and neck? An anatomical study by the tissue platination technique. *Plast Reconstr Surg* 111(2):664–672
7. Ghassemi A, Prescher A, Riediger D, Axer H (2003) Anatomy of the SMAS revisited. *Aesthetic Plast Surg* 27(4):258–264
8. Wobig JL, Dailey RA (2004) Facial anatomy. In: Wobig JL, Dailey RA (eds) *Oculofacial plastic surgery*. Thieme, New York, p 5
9. Jones BM, Grover R (2008) Anatomical considerations. In: Jones BM, Grover R (eds) *Facial rejuvenation surgery*. Mosby Press, London, pp 18–22
10. Mendelson BC, Freeman ME, Wu W, Huggins RJ (2008) Surgical anatomy of the lower face: the premasseter space, the jowl, and the labiomandibular fold. *Aesthetic Plast Surg* 32(2):185–195
11. Rohrich R, Arbique GM, Wong C, Brown S, Pessa JE (2009) The anatomy of suborbicularis fat: implications for peri-orbital rejuvenation. *Plast Reconstr Surg* 124(3):946–951
12. Mendelson BC, Muzaffar AR, Adams WP (2002) Surgical anatomy of the midcheek and malar mounds. *Plast Reconstr Surg* 110(3):885–896
13. Larrabee WF, Makielski KH, Henderson JL (2004) Cheeks and neck. In: Larrabee WF, Makielski KH, Henderson JL (eds) *Surgical anatomy of the face*. Lippincott Williams & Wilkins, Philadelphia, p 178
14. Zide BM (2006) ROOF and beyond (superolateral zone). In: Zide BM, Jelks GW (eds) *Surgical anatomy around the orbit. The system of zones*. Lippincott Williams & Wilkins, Philadelphia, p 57
15. Rohrich RJ, Pessa JE (2010) The subplatysmal supramylohyoid fat. *Plast Reconstr Surg* 126(2):589–595
16. Connell BF, Shamoun JM (1997) The significance of digastric muscle contouring for rejuvenation of the submental area of the face. *Plast Reconstr Surg* 99(6):1586–1590
17. De Castro CC (2000) The changing role of platysma in face lifting. *Plast Reconstr Surg* 105(2):764–775
18. De Castro CC (1980) The anatomy of the platysma muscle. *Plast Reconstr Surg* 66(5):680–683
19. Labbe D, Franco RG, Nicolas J (2006) Platysma suspension and platysmaplasty during neck lift. Anatomical study and analysis of 30 cases. *Plast Reconstr Surg* 117(6):2001–2007
20. Zide BM (2006) Supraorbital nerve. Nuances/dissections from above. In: Zide BM, Jelks GW (eds) *Surgical anatomy around the orbit. The system of zones*. Lippincott Williams & Wilkins, Philadelphia, p 77
21. Berkovitz BKB, Moxham BJ (2002). *Head and neck anatomy. a clinical reference*, Martin Dunitz, London, p 118
22. Silva MT, Curi AL (2004) Blindness and total ophthalmoplegia after aesthetic polymethylmethacrylate injection: case report. *Arg Neuropsiquiatr* 62(3B):873–874
23. McCleve D, Goldstein JC (1995) Blindness secondary to injections in the nose, mouth, and face: cause and prevention. *Ear Nose Throat J* 74:182–188
24. Dreizen NG, Framm L (1989) Sudden unilateral visual loss after autologous fat injection into the glabellar area. *Am J Ophthalmol* 107:85–87
25. Coleman SR (2002) Avoidance of arterial occlusion from injection of soft tissue fillers. *Aesthet Surg J* 22(6):555–557



<http://www.springer.com/978-3-642-21836-1>

Cosmetic Surgery

Art and Techniques

Shiffman, M.A.; Di Giuseppe, A. (Eds.)

2013, XV, 1192 p. 86 illus., 75 illus. in color., Hardcover

ISBN: 978-3-642-21836-1